

SUCCESSFUL TREATMENT OF ANTEROLATERAL LIGAMENT TEAR OF THE KNEE WITH ULTRASOUND-GUIDED PLATELET-RICH PLASMA INJECTION: A CASE REPORT

Cheng WL¹, George J², Jaafar Z^{1,3*}, Lim WK,² and Hussein KH².

¹Sports Medicine Unit, Faculty of Medicine, Universiti Malaya, 50603 Kuala Lumpur, Malaysia

²Pusat Perubatan Sukan Negara, Institut Sukan Negara Kompleks Sukan Negara, Bukit Jalil, 57000 Kuala Lumpur, Malaysia

³Sports and Exercise Medicine Research and Education Group, Faculty of Medicine, Universiti Malaya, 50603 Kuala Lumpur, Malaysia

Correspondence:

Zulkarnain Jaafar,
Sports Medicine Unit,
Faculty of Medicine,
Universiti Malaya, 50603 Kuala Lumpur, Malaysia
Email: zulkarnainj@um.edu.my

Abstract

Type 1 and type 2 anterolateral ligament (ALL) or meniscocapsular tears are frequently treated conservatively. However, the initiation of the healing process of these tears could take up to six weeks, and about 70% of acute ALL injuries demonstrated poor healing at the 1-year follow-up. This case report describes the successful treatment of an MRI-confirmed ALL tears by direct injection of platelet-rich plasma (PRP) into the ALL and adjacent anterolateral meniscocapsular tears under ultrasound guidance. This treatment yielded excellent outcome with complete relief of pain six weeks after the injection, and repeated ultrasound examination showed 80% restoration of the torn tissues.

Keywords: Ligaments, Tears, Meniscus, Regenerative, Imaging, Platelet-rich Plasma, Anterolateral Ligament, Ultrasound-guided Injection

Introduction

Anterolateral ligament (ALL) was first mentioned by Paul Segond in 1879, after he reported an avulsion fracture of a fibrous band at the anterolateral portion of proximal tibia (1). However, this fibrous band was only given its name in 2012 by Vincent et al (2). Despite being reported in numerous literature the presence and prevalence of ALL is still debatable, and some authors still question its existence (3). ALL injury occurs concomitantly with an anterior cruciate ligament (ACL) due to a higher degree tibial internal rotation and increased pivot shift during trauma; however, isolated ALL injury does occur (4, 5). In fact, ALL lesions are difficult to diagnose even by experienced clinicians due to no available validated clinical tests, making ALL tears not commonly recognised and most of the time, left untreated (6). ALL play a crucial role in the rotational stability of the knee especially internal rotation (5) and ALL reconstruction are to minimize the ACL graft re-rupture rate. At present, there is no clear guideline on ALL injury management, but a diversity of surgical procedures related to lateral extra-articular reconstruction or tenodesis had been reported (7).

Platelet-rich plasma (PRP) is an autologous blood sample in which the platelet concentration is higher in comparison with normal blood plasma (8) and it has been used in

many different parts of the world for injury treatment. PRP injection is fairly safe and the complications are commonly related to phlebotomy and injection, such as minor bleeding, hematoma, and infection (9). Research has shown positive outcomes in the treatment of muscle tears and tendinopathies using PRP, but its evidence on ligament injury treatment is still limited (10). In view of conservative management of ALL injury, we wish to report a case of a recreational squash player with MRI-confirmed ALL and meniscocapsular tears which were treated conservatively using platelet-rich plasma (PRP) through direct injection of the tears under ultrasound guidance.

Case Presentation

A 16-year-old male recreational squash player complained of right knee pain for a year. He buckled his right knee while changing direction during a squash game a year ago. He denied hearing any 'pop' sound, having locking sensation, or feeling give-way. The injury was associated with mild knee swelling. Despite the injury, he did not seek any medical treatment and continued playing. However, since then, he experienced on and off knee pain, which worsened during activities such as running, jumping, and squatting. At times, he felt pain during walking or climbing stairs. The

pain was sharp and localized to the anterolateral aspect of his knee. He denied any instability symptoms. He was a student and he denied smoking or taking alcohol. There was no significant family history other than that his father had hypertension.

Physical examination revealed tenderness over the lateral collateral ligament (LCL) and anterolateral knee joint line, and no tenderness elsewhere. There was no swelling in the knee joint or the surrounding structures, and the range of motion was full and equal on both sides. Varus stress test, anterior drawer test, tibial internal rotation test, as well as other ligamentous examinations were negative. The McMurray test and Thessaly test were also negative. During functional assessments, he was able to perform squats and lunges without any pain or difficulties. MRI findings revealed ALL tears with meniscocapsular tears of the anterolateral portion of the lateral meniscus with an intact meniscus. In addition, a mild attenuation of the mid portion of the LCL was noted to be present.

Management plans were discussed with the patient and his father, which included both non-operative and operative. They decided to go for ultrasound-guided PRP injection of the ALL and meniscocapsular tears. The pros and cons, as well as the limited evidence of ultrasound-guided PRP injection to treat this condition, were made known to them. A written informed consent was obtained from the patient's father and assent was obtained from him for the procedure.

A senior musculoskeletal radiologist performed the ultrasound-guided PRP injection. Ultrasound examination showed 90% ALL fiber tears together with anterolateral meniscocapsular tears (Figure 1). The PRP preparation was as follows: 30 mL of peripheral whole blood was withdrawn from the patient and, using BIOMET GPS III Mini Platelet Concentration Kit (BIOMET Biologics, Warsaw, IN, USA), 3 mL of PRP were obtained. Then, the patient was placed in a left lateral recumbent position and his right knee was prepared using sterile technique. A 22-gauge needle was introduced through the skin under Philips Epiq 5 ultrasound machine guidance (Philips Healthcare, Best, Netherlands) using a high frequency linear transducer (18-5 MHz), with the needle placed in-plane relative to the transducer and longitudinal to Iliotibial band (ITB). Three mL of autologous PRP were injected to the anterolateral capsular region layer under the ITB. Finally, a sterile dressing was applied at the injection site. The injection was uneventful, and the patient tolerated the procedure well.

After the procedure, he was advised to keep the injection site clean and avoid strenuous physical activities until his follow-up schedule in 2 weeks' time. He was instructed not to take any anti-inflammatory medications, and to take paracetamol tablets 1000 mg, only if he had any unbearable pain. At two weeks, he started his progressive rehabilitation program with the physiotherapist, which included a range of motion and strengthening exercises. During the subsequent follow up at six weeks, he expressed complete resolution of symptoms, while the ultrasound

examination showed an 80% healing and reformation of ALL and anterolateral meniscocapsular tears (Figure 2).

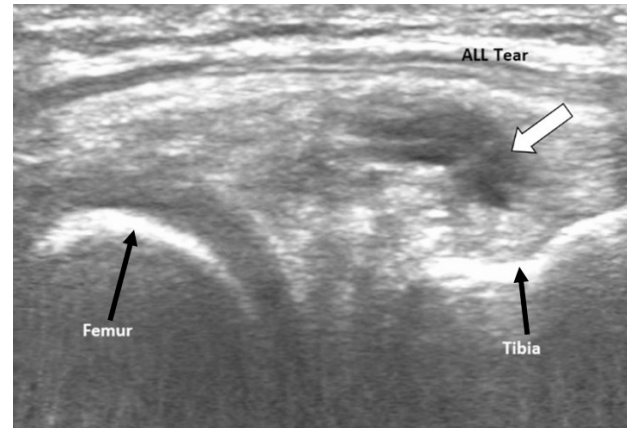


Figure 1: ALL and anterolateral meniscocapsular tears on ultrasound before PRP injection

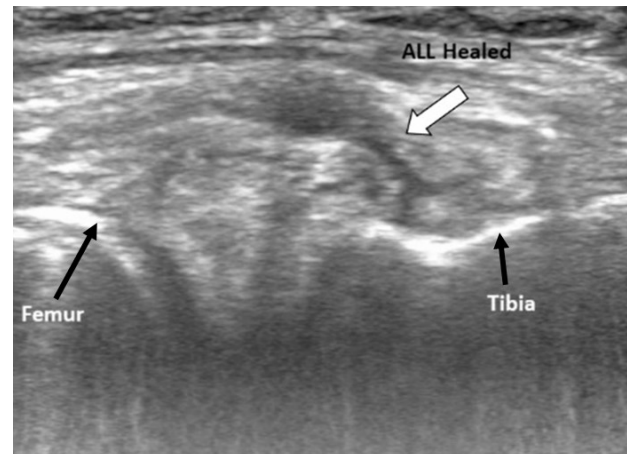


Figure 2: Ultrasound findings post PRP injection showed restoration of normal appearance of the ALL with 80% of the ligament fibers visualized

Discussion

The diagnosis of ALL and meniscocapsular tears is challenging (6, 11, 12); in this case, we did not get a distinctive history which suggested ALL injury. Thus, in ALL suspected cases, a detailed history describing the mechanism of injury and a thorough clinical examination are necessary to diagnose these conditions. The mechanism of ALL injury is similar to an ACL injury that involves early flexion, dynamic valgus, and internal rotation of the knee (13). However, if the history does not suggest ALL injury, special attention should be given to the lateral compartment of the knee during examination to elicit any bruise, swelling, or tenderness, and at the same time assessing the integrity of other ligaments at the knee carefully.

Radiographic examinations are important to confirm ALL or meniscocapsular tears. Although coronal MRI is

helpful in diagnosing ALL injuries with a detection rate up to 97.8% (11, 14), ultrasound imaging is deemed to be a reliable tool that can detect this injury at a faster rate. The use of ultrasound as first line investigation for ALL suspected injury provides greater benefits because it is a reproducible tool that saves time and cost, and at the same time visualizes the ligament in real time in any knee position (15, 16).

In clinical practice, type 1 and type 2 anterolateral meniscocapsular tears are treated conservatively, from anecdotal experiences these tears could take up to six weeks for the healing process to occur. As for ALL tears, Lee *et al.* in his publication found that up to 70% of acute ALL injuries demonstrated poor healing at 1-year follow-up, and may contribute to rotational instability after ACL reconstruction (17). Nonetheless, many studies have been supportive but not conclusive in saying that surgical reconstruction is necessary (3, 11, 17, 18). Despite all the positive notes, surgical interventions could expose patients to other surgical and anaesthetic complications.

PRP is a current method which has been frequently used in treating soft tissue injuries such as muscle tears or tendinopathies but the evidence on its use on ligament injury is still scarce (19, 20). Nonetheless, the effectiveness of PRP use in ligament injury treatment is still uncertain in view of limited randomized controlled trials mentioned in the literature, except for ACL and ulnar collateral ligament (21, 22). To the best of our knowledge, there was no reported case of treating ALL injury with PRP injection prior to this. Hence, more high-quality randomized controlled trials are necessary to determine the efficacy of this procedure in treating ligament injuries.

Conclusion

This is a case of successful treatment of ALL tear of the knee with ultrasound-guided platelet-rich plasma injection. This finding evinced the role of PRP in promoting and accelerating the healing of ALL and it should be considered as the first line of treatment to treat this condition prior to surgical correction.

Perspective

From the evidence we gathered, we believe PRP is a practical and effective option in treating ligament injuries. This case provides the basis for future exploration of PRP usage in treating different grade of ligament tears.

Financial support

The authors declare that this study received no financial support.

Competing interests

The authors declare that they have no competing interest.

Consent

Written informed consent and assent were obtained from the guardian and patient involved in this study.

References

1. Claes S, Vereecke E, Maes M, Victor J, Verdonk P, Bellemans J. Anatomy of the anterolateral ligament of the knee. *J Anat.* 2013;223(4):321-8.
2. Vincent JP, Magnussen RA, Gezmez F, Uguen A, Jacobi M, Weppe F, *et al.* The anterolateral ligament of the human knee: an anatomic and histologic study. *Knee Surg Sports Traumatol Arthrosc.* 2012;20(1):147-52.
3. Musahl V, Rahnama-Azar AA, van Eck CF, Guenther D, Fu FH. Anterolateral ligament of the knee, fact or fiction? *Knee Surg Sports Traumatol Arthrosc.* 2016;24(1):2-3.
4. Claes S, Bartholomeeusen S, Bellemans J. High prevalence of anterolateral ligament abnormalities in magnetic resonance images of anterior cruciate ligament-injured knees. *Acta Orthop Belg.* 2014;80(1):45-9.
5. Rasmussen MT, Nitri M, Williams BT, Moulton SG, Cruz RS, Dornan GJ, *et al.* An in vitro robotic assessment of the anterolateral ligament: II. Anterolateral ligament reconstruction combined with anterior cruciate ligament reconstruction. *Am J Sports Med.* 2016;44(3):593-601.
6. Slichter ME, Wolterbeek N, Auw Yang KG, Zijl J, Piscaer TM. A novel test for assessment of anterolateral rotatory instability of the knee: the tibial internal rotation test (TIR test). *J Exp Orthop.* 2018;5(1):29.
7. Musahl V, Herbst E, Burnham JM, Fu FH. The anterolateral complex and anterolateral ligament of the knee. *J Am Acad Orthop Surg.* 2018;26(8):261-7.
8. Alves R, Grimalt R. A review of platelet-rich plasma: history, biology, mechanism of action, and classification. *Skin Appendage Disord.* 2018;4(1):18-24.
9. O'Connell B, Wragg NM, Wilson SL. The use of PRP injections in the management of knee osteoarthritis. *Cell Tissue Res.* 2019;376(2):143-52.
10. Cruciani M, Franchini M, Mengoli C, Marano G, Pati I, Masiello F, *et al.* Platelet-rich plasma for sports-related muscle, tendon, and ligament injuries: an umbrella review. *J Blood Transfus.* 2019;17(6):465.
11. Sonnery-Cottet B, Daggett M, Fayard J-M, Ferretti A, Partezani-Helito C, Lind M, *et al.* Anterolateral ligament expert group consensus paper on the management of internal rotation and instability of the anterior cruciate ligament - deficient knee. *J Orthop Trauma.* 2017;18(2),91-106. <https://doi.org/10.1007/s10195-017-0449-8>
12. George J, Saw KY, Ramlan AA, Packya N, Tan AH, Paul G. Radiological classification of meniscocapsular tears of the anterolateral portion of the lateral meniscus of the knee. *Australas Radiol.* 2000;44:19-22.

13. Davis DS, Post WR. Segond fracture: lateral capsular ligament avulsion. *J Orthop Sports Phys Ther.* 1997;25(2):103–6. doi:10.2519/jospt.1997.25.2.103
14. Helito CP, Helito PV, Costa HP, Bordalo-Rodrigues M, Pecora JR, Camanho GL, *et al.* MRI evaluation of the anterolateral ligament of the knee: assessment in routine 1.5-T scans. *Skeletal radiol.* 2014;43(10):1421-7.
15. Capo J, Kaplan DJ, Fralinger DJ, Adler RS, Campbell KA, Jazrawi LM, *et al.* Ultrasonographic visualization and assessment of the anterolateral ligament. *Knee Surg Sports Traumatol Arthrosc.* 2017;25(10):3134-9.
16. Cavaignac E, Faruch M, Wytrykowski K, Constant O, Murgier J, Berard E, *et al.* Ultrasonographic Evaluation of anterolateral ligament injuries: correlation with magnetic resonance imaging and pivot-shift testing. *Arthroscopy.* 2017;33(7):1384-90.
17. Lee DW, Kim JG, Kim HT, Cho SI. Evaluation of anterolateral ligament healing after anatomic anterior cruciate ligament reconstruction. *Am J Sports Med.* 2020;48(5):1078-87. doi:10.1177/0363546520908805
18. Kraeutler MJ, Welton KL, Chahla J, LaPrade RF, McCarty EC. Current concepts of the anterolateral ligament of the knee: anatomy, biomechanics, and reconstruction. *Am J Sports Med.* 2018;46(5):1235-42.
19. Kon E, Filardo G, Delcogliano M, Presti ML, Russo A, Bondi A, *et al.* Platelet-rich plasma: new clinical application: a pilot study for treatment of jumper’s knee. *Injury.* 2009;40(6):598–603.
20. Le ADK, Enweze L, DeBaun MR, Dragoo JL. Platelet-rich plasma. *Clin Sports Med.* 2019;38(1):17-44. doi:10.1016/j.csm.2018.08.001
21. Kia C, Baldino J, Bell R, Ramji A, Uyeki C, Mazzocca A. Platelet-rich plasma: review of current literature on its use for tendon and ligament pathology. *Curr Rev Musculoskelet Med.* 2018;11(4):566-72. doi: 10.1007/s12178-018-9515-y.
22. Chen X, Jones IA, Park C, Vangsnest CT Jr. The efficacy of platelet-rich plasma on tendon and ligament healing: a systematic review and meta-analysis with bias assessment. *Am J Sports Med.* 2018;46(8):2020-32. doi:10.1177/0363546517743 746.